

Type 1 Brugada Type-ECG Pattern Provoked by Fever in a Patient with COVID-19

Firdevs ULUTAS¹, Asli BOZDEMIR², Ibrahim OGUZ³, Mithat KAHRAMANOGLU⁴, Veli COBANKARA¹, Ismail Hakki AKBUDAK⁴

¹Pamukkale University, Division of Rheumatology, Department of Internal Medicine, Denizli, Turkey

²Pamukkale University, Department of Internal Medicine, Denizli, Turkey

³Pamukkale University, Department of Cardiology, Denizli, Turkey

⁴Pamukkale University, Department of Intensive Care Unit, Denizli, Turkey

Cite this article as: Ulutas F, Bozdemir A, Oguz I, Kahramanoglu M, Cobankara V, Akbudak IH. Type 1 Brugada Type-ECG Pattern Provoked by Fever in a Patient with COVID-19.

Corresponding Author: Firdevs Ulutas
E mail: firdevsulutas1014@gmail.com

©Copyright 2021 by Turkish Society of Medical and Surgical Intensive Care Medicine - Available online at www.dcyogunbakim.org

Received: Jun 28, 2021

Accepted: Jul 13, 2021

Available online: Sep 21, 2021

ABSTRACT

The novel severe acute respiratory syndrome coronavirus-2 (SARS-CoV-2) related coronavirus disease 2019 (COVID-19) has been declared as a global pandemic by the World Health Organization. Brugada Syndrome (BrS) has been shown to occur spontaneously in patients with a viral infection, and the fever is the culprit trigger in the underlying mechanism. Herein, we described a patient who presented with syncope and Brugada-type electrocardiogram (ECG) pattern and diagnosed with COVID-19 pneumonia. The patient was taken to the intensive care unit for continuous ECG recording and monitoring. Favipiravir, low molecular weight heparin, high flow oxygen therapy, and antipyretic therapy were initiated. Brugada-type ECG pattern was disappeared with a resolution of fever. ECG findings of BrS may occur during fever and may lead to life-threatening arrhythmic events in unknown subjects. This clinical condition may require a subcutaneous implantable cardioverter-defibrillator in some patients. ECG should be a part of clinical evaluation in patients with COVID-19 even though without syncope.

Keywords: COVID-19, Brugada syndrome, electrocardiogram, fever

Introduction

The novel severe acute respiratory syndrome coronavirus 2 (SARS-CoV-2) related coronavirus disease 2019 (COVID-19) has been declared as a global pandemic by the World Health Organization. Various clinical findings such as fever, cough, shortness of breath, fatigue, myalgia, arthralgia, headache, diarrhea, sore throat, and sputum can often be seen in infected patients (1). In many COVID-19 cases, it has been noted that the virus can also provoke vascular inflammation, acute myocardial injury, myocarditis, arrhythmias, venous thromboembolism, metabolic syndrome, and Kawasaki disease that may be linked to myocarditis, inflammation, or microvascular thrombosis. There are also accumulated case reports related to Brugada Syndrome (BrS) and COVID-19 in the recent literature (2). BrS is an inherited cardiac arrhythmia syndrome characterized by an increased risk of ventricular fibrillation, sudden cardiac death, and specific abnormal electrocardiogram (ECG) patterns in healthy individuals without structural heart disease. Patients are usually asymptomatic for life-span and are diagnosed incidentally with

the Brugada ECG pattern. BrS has been shown to occur spontaneously in patients with a viral infection, and the fever is a culprit trigger in the underlying pathophysiological mechanism. A link between fever and a Brugada-type I pattern can be explained by the inactivation of sodium channels and phase 2 re-entry ventricular arrhythmias due to reduced-sodium flow (3). Mutations in the SCN5A and SCN10A genes related to cardiac sodium channels were identified as culprit factors in the pathogenesis (4). In addition, many provocative triggers related to COVID-19 such as stress, hypoxia, electrolyte disturbances, and medications lead to arrhythmic heart diseases. Possible direct effects of the virus on the myocardial ion channels are also possible (5).

Herein, we described a patient who presented with syncope and Brugada-type ECG pattern and diagnosed with COVID-19 pneumonia.

Case

A 67-year-old man with type 2 diabetes mellitus and hypertension was admitted to the emergency department with loss of consciousness

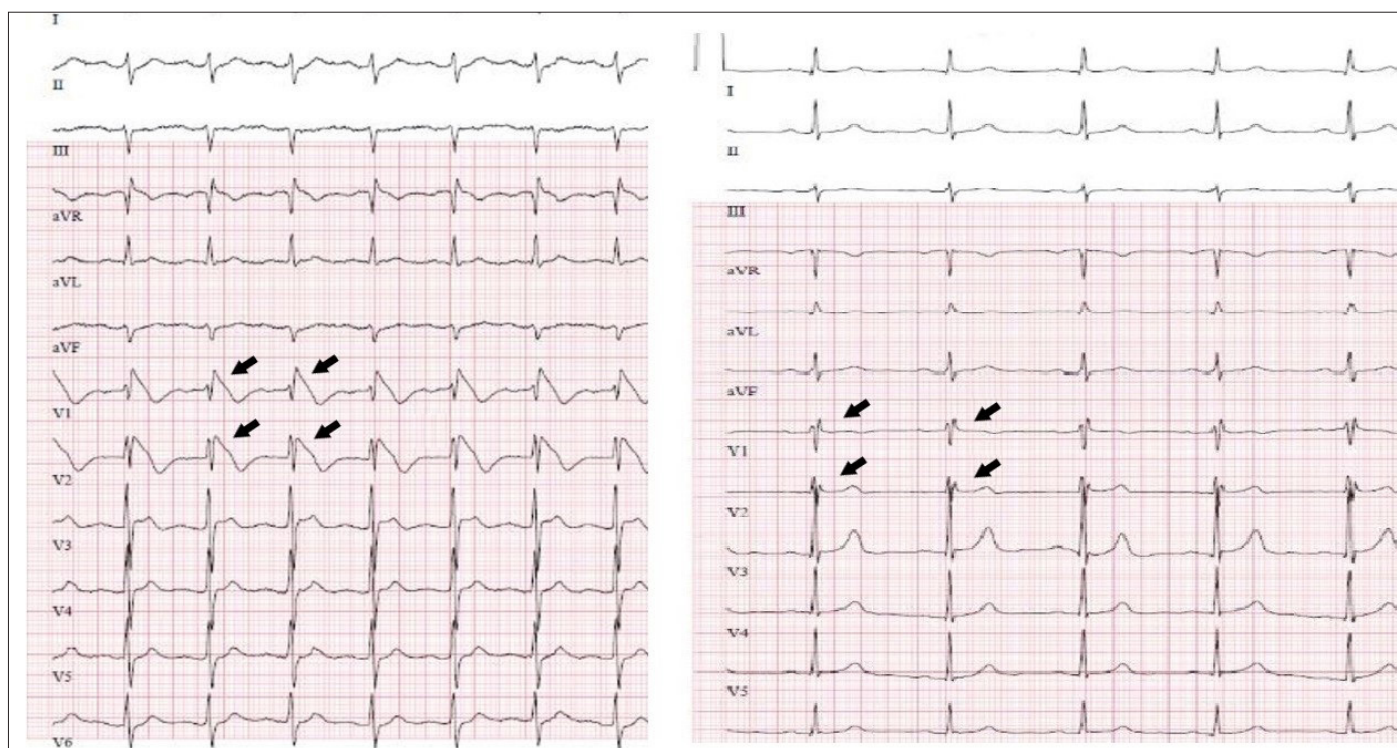


Figure 1-2 (side by side). The first 12-lead electrocardiogram (ECG) shows on V1-V2 derivations typical Brugada Type-1 pattern at the time of 38.4°C fever (left). The second ECG shows normalization of the typical pattern while the fever is normal (right).

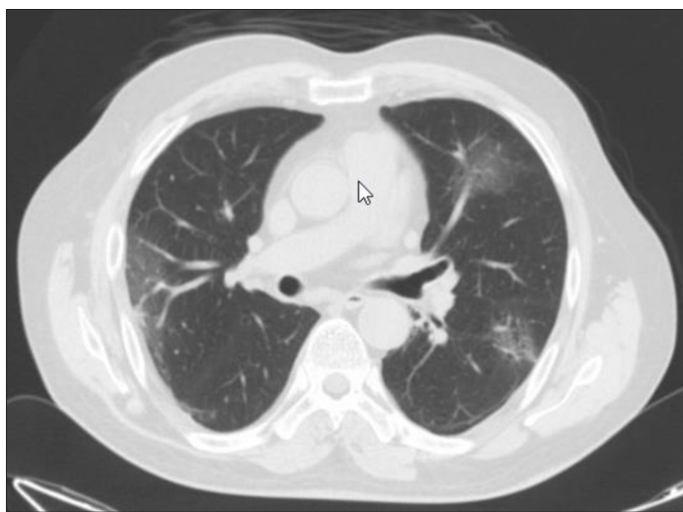


Figure 2. Thoracic computerized tomography (CT): Viral pneumonia representing diffuse ground glass infiltrations.

and syncope. There was no history of sudden cardiac death or neurological disease in his family or history. The patient's Glasgow coma scale was recorded as 15 points, blood pressure 134/60 mm/Hg, pulse: 100 beats/minute, fever: 38.4°C, oxygen saturation 97%. On physical examination, heart sounds were rhythmic. Emergent first ECG showed concave (coved) ST-segment elevation and T wave negativity in V1-V2 leads, and ST-segment elevation in V3 leads, and it was evaluated as type 1 Brugada pattern (Figure 1 left ECG). Thoracic computerized tomography (CT) was compatible with viral pneumonia representing diffuse ground glass infiltrations (Figure 2). Combined nasal-throat viral swab samples were positive

for SARS-CoV-2. Biochemical tests have been resulted as C-reactive protein: 46.25 mg/L, lactate dehydrogenase: 274U/L, ferritin: 438 ug/L, fibrinogen: 511 mg/dL, D-dimer: 395 ng/mL, white blood cell: 10.11 K/uL neutrophil: 9.43 K/uL, lymphocyte: 0.55 K/uL, hemoglobin 11.8 g/dL, creatine kinase MB (CK-MB): 1.22 ug/L, myoglobin: 63.1 ug/L and troponin-T: 16.2 ng/L. The patient was taken to the intensive care unit for continuous ECG recording and monitoring, and close monitoring of temperature, arterial blood pressure, and vital signs. Favipiravir, low molecular weight heparin, high flow oxygen therapy, and antipyretic therapy were initiated. The patient was followed closely for syncope and worsened cardiac arrhythmias, and cardiac markers were evaluated daily. Bedside echo-cardiography showed no structural anomaly. Resolution of the Brugada-type ECG pattern was observed in the follow-up as soon as the temperature decreased (Figure 1 right ECG).

Discussion

An interesting finding, in this case, is that he presented after an episode of syncope, and was ultimately diagnosed with COVID-19 pneumonia. The patient was completely unaware of his arrhythmogenic predisposition. He had no family history of sudden death or syncope/palpitation anamnesis before. This clinical condition occurred during high fever due to COVID-19 viral infection. Today it is well-known that the BrS is responsible for 4% to 12% of all sudden deaths, and 20% of these deaths occur in patients who have normal heart structure. Up to 30% of patients with BrS carry a loss-of-function in SCN5A (6).

There are many cases of COVID-19 related BrS in the recent literature. Chang D et al. described a 49-year-old man who was

presented with syncope and had a good prognosis in the follow-up with antipyretics as well as in our patient (7). However, Pasquetto G et al. had to use subcutaneous implantable cardioverter-defibrillator in their patients due to unresponsiveness to supportive treatment modalities (8). Another important point in these patients, any factor during ICU management such as anesthetics, vagotonic agents, beta-adrenergic blockers, alpha-adrenergic agonists, thermal variations, hypovolaemia that unbalances the parasympathetic and sympathetic traffic may precipitate a lethal arrhythmia (9). Choi NH et al. emphasized avoiding the use of Propofol and Bupivacaine in these patients as they did in their cases (10). Male dominance, presenting with syncope, fever, shortness of breath, and new chest pain, having a median age between 40–60 are common features among patients with BrS provoked by COVID-19 in the recent literature. The majority of patients have a good prognosis and are usually responsive to antipyretic treatment (11). Some life-threatening arrhythmic events may require a subcutaneous implantable cardioverter-defibrillator as mentioned

above (8). These factors should be taken into consideration while management of the patient's disease. The benign course in our patient did not require further treatment options.

There was not available knowledge about the genetic predispositions of most BrS patients in the literature. We could not also examine genetic tests for SCN5A variants in the patient due to technical limitations.

Conclusion

Fever, which is one of the main symptoms of COVID-19, led to the diagnosis of a significant number of asymptomatic BrS patients during the COVID-19 pandemic. ECG should be a part of clinical evaluation in patients with COVID-19 even though without syncope. Although fever is a pro-arrhythmic stressor factor, further studies are needed to elucidate cardiac etiologies in patients infected with COVID-19.

AUTHOR CONTRIBUTIONS:

Concept: FU, AB, ID; **Design:** FU; **Supervision:** FU, VC, IHA; **Materials:** MK, IO, FU; **Data Collection and/or Processing:** MK, IO, FU; **Analysis and/or Interpretation:** FU, AS, IHA; **Literature Search:** FU, IHA; **Writing Manuscript:** FU, IHA; **Critical Review:** FU, IHA.

Informed Consent: From the patient himself

Peer-review: Externally peer-reviewed.

Conflict of Interest: Authors have no conflicts of interest to declare.

Financial Disclosure: The authors declared that this study has received no financial support.

References

- Chams N, Chams S, Badran R, et al. COVID-19: A Multidisciplinary Review. *Front Public Health* 2020;8:383. <https://doi.org/10.3389/fpubh.2020.00383>
- Chang W-T, Toh HS, Liao C-T, et al. Cardiac Involvement of COVID-19: A Comprehensive Review. *Am J Med Sci* 2021;361:14–22. <https://doi.org/10.1016/j.amjms.2020.10.002>
- Antzelevitch C, Brugada R. Fever and Brugada syndrome. *Pacing Clin Electrophysiol* 2002;25:1537–9. <https://doi.org/10.1046/j.1460-9592.2002.01537.x>
- Hu D, Barajas-Martinez H, Pfeiffer R. Mutations in SCN10A are responsible for a large fraction of cases of Brugada syndrome. *J Am Coll Cardiol* 2014;64:66–79. <https://doi.org/10.1016/j.jacc.2014.04.032>
- Sorgente A, Capulzini L, Brugada P. The Known Into the Unknown: Brugada Syndrome and COVID-19. *JACC Case Rep* 2020;2:1250–1. <https://doi.org/10.1016/j.jaccas.2020.04.006>
- Antzelevitch C, Brugada P, Brugada J, et al. Brugada syndrome: a decade of progress. *Circ Res* 2002;91:1114–8. <https://doi.org/10.1161/01.res.0000046046.53721.90>
- Chang D, Saleh M, Garcia-Bengo Y, et al. COVID-19 Infection Unmasking Brugada Syndrome. *HeartRhythm Case Rep* 2020;6:237–40. <https://doi.org/10.1016/j.hrcre.2020.03.012>
- Pasquetto G, Conti GB, Susana A, et al. Syncope, Brugada syndrome, and COVID-19 lung disease. *J Arrhythm* 2020;36:768–70. <https://doi.org/10.1002/joa3.12375>
- Dendramis G, Brugada P. Intensive care and anesthetic management of patients with Brugada syndrome and COVID-19 infection. *Pacing Clin Electrophysiol* 2020;43:1184–9. <https://doi.org/10.1111/pace.14044>
- Choi NH, Silver ES, Fremed M, et al. COVID-19 reveals Brugada pattern in an adolescent patient. *Cardiol Young* 2020;30:1735–7. <https://doi.org/10.1017/s1047951120002619>
- Wu C-I, Postema PG, Arbelo E, et al. SARS-CoV-2, COVID-19, and inherited arrhythmia syndromes. *Heart Rhythm* 2020;17:1456–62. <https://doi.org/10.1016/j.hrthm.2020.03.024>