

Extracorporeal Carbondioxide Removal in Near Fatal Asthma Attack: A Case Report

Pervin HANCI¹ , Cansin ERER¹ 

¹Trakya University Faculty of Medicine, Pulmonology, Edirne, Turkey

Cite this article as: Hanci P, Erer C. Extracorporeal Carbondioxide Removal in Near Fatal Asthma Attack: A Case Report. J Crit Intensive Care 2023;14:24–27

Corresponding Author: Pervin Hanci
E mail: pervinhanci@hotmail.com

Received: Jan 15, 2023

Accepted: Feb 15, 2023

Available online: Mar 06, 2023

ABSTRACT

Objective: Status asthmaticus is seen in 3-10 % of asthma patients and can cause near-fatal asthma attacks. A near-fatal asthma attack is defined as a severe exacerbation of asthma that may require mechanical ventilation associated with respiratory arrest, altered consciousness, and/or PaCO₂ over 50 mmHg. Invasive mechanical ventilation is required in 30% of patients, and mortality is 8% in these patients. Although mechanical ventilation can often provide adequate oxygenation and ventilation, ventilator-associated lung injury may occur due to increased dynamic hyperinflation of the lung. Extracorporeal methods are indicated in patients whose respiratory failure couldn't be healed with mechanical ventilation. This report presents a near-fatal asthma attack patient managed with an extracorporeal carbon dioxide removal filter (ECCO₂R).

Case: A 22-year-old female patient with asthma was admitted to the emergency department with shortness of breath. Besides pharmacological treatment, the patient was deteriorated and intubated. The patient was admitted to the ICU. Blood gas analysis showed respiratory and metabolic acidosis (pH: 6.9, PaCO₂: 132 mmHg, PaO₂:99 HCO₃: 19.5 mmol/L). Bilateral hyperinflation was seen on Chest X-Ray (image), and severe respiratory wheezing was heard in both lungs. Mechanical ventilator settings (PCV mode, FiO₂:50%, PEEP:0 cmH₂O, Pinspirum:35 cmH₂O, respiratory rate: I/E:1/3.5) were made to prevent barotrauma. Otopeep was measured as six cmH₂O with an expiratory hold maneuver. The maximum tidal volume was measured as 250 ml. ECCO₂R system was initiated for ongoing respiratory acidosis with a 4 L/min sweep gas flow. Half an hour after starting the ECCO₂R system, blood gas analysis was normal (pH: 7.40, PaCO₂: 36 mmHg, PaO₂:184 mmHg, HCO₃:23 mmol/L). On day 4, the bronchospasm was resolved completely, and respiratory system compliance increased. The sweep gas flow rate was titrated down, and the device support was discontinued on day 5. The patient was extubated after a successful spontaneous breathing trial on day six and discharged.

Result: Extracorporeal devices could be helpful in near-fatal asthma attack that is hard to manage with invasive mechanical ventilation. In cases where oxygenation can be maintained with a mechanical ventilator, and persistent hypercapnia is present, patients could benefit from ECCO₂R.

Keywords: asthma, extracorporeal devices, respiratory failure, hypercapnia

Introduction

Acute asthma attack is an exacerbation of disease characterized by a progressive increase in symptoms like shortness of breath, cough, wheezing, or chest tightness and a decrease in lung function, requiring a change in treatment (1). Respiratory tract viral infections, exposure to allergens and air pollution, or poor adherence to treatment are common exacerbation triggers. (2,3). Exacerbation severity is assessed by the patient's history, symptoms, physical examination, oxygenation, and pulmonary function test. Agitation, restlessness, talking in words, accessory respiratory muscle usage, tachypnea (respiratory rate >30/min), tachycardia (pulse rate >120/min), and desaturation are the physical examination

findings associated with severe exacerbation (4). A near-fatal asthma attack is defined as an acute severe asthma attack requiring mechanical ventilation due to respiratory failure, hypercapnia (PaCO₂>50 mmHg) with or without altered consciousness, or respiratory arrest. (5) Invasive mechanical ventilation (IMV) is required in 30% of patients with severe asthma attacks (6). The mortality of these patients is about 10-25% (7,8).

Mechanical ventilation can often provide adequate oxygenation and carbon dioxide extraction in patients with asthma attacks. However, ventilatory associated lung injury risk is high due to dynamic hyperinflation of the lungs. Extracorporeal methods are indicated in patients

Available online at
<http://www.jcritintensivecare.org/>



Content of this journal is licensed under a Creative Commons Attribution-NonCommercial 4.0 International License.

whose respiratory failure cannot be managed with mechanical ventilation (9). The extracorporeal carbon dioxide removal (ECCO₂R) system is used successfully to prevent intubation or ventilatory-associated complications in the presence of severe respiratory acidosis (10). This report presents a near-fatal asthma attack patient managed with an extracorporeal carbon dioxide removal filter (ECCO₂R).

Case Presentation

A 22-year-old woman with a history of asthma presented to our emergency room with complaints of sudden onset dyspnea. The patient was diagnosed with asthma when she was three-year-old. Her relatives stated that she was not compliant with medications and was an active smoker. She was working in a construction company's occupational health and safety unit. She had a history of hospitalization for asthma attacks and pneumonia once a year for the last 10 years. In 2019, she was admitted to the intensive care unit due to a severe asthma attack and she required chest thoracotomy tube placement for bilateral pneumothorax.

On physical examination, she was agitated and had severe respiratory distress with expiratory wheezing. She was evaluated as having an asthma attack; supplemental oxygen, inhalative salbutamol and budesonide, intravenous methylprednisolone, theophylline, and magnesium were administered. Initial arterial blood gas analysis demonstrated primary respiratory acidosis at pH: 7.17, partial pressure of oxygen (PaO₂) 69.9 mmHg, partial pressure of carbon dioxide (PaCO₂) 75 mmHg, oxygen saturation (SaO₂) %89 and bicarbonate (HCO₃) 20 mmol/L. Chest X-Ray showed air trapping (Figure 1).

The patient was intubated and admitted to our intensive care unit (ICU). Invasive mechanical ventilation was started with sedation and analgesia. Arterial blood gas obtained at ICU admission revealed respiratory and metabolic acidosis both (pH: 6.9, PaCO₂: 132 mmHg, PaO₂:99 HCO₃: 19.5 mmol/L). OtopEEP was measured as 6 cmH₂O with an expiratory hold manoeuvre. The maximum tidal volume was measured as 250 ml and respiratory system dynamic compliance was under 30 mL/cmH₂O. Mechanical ventilator settings (PCV mode, FiO₂:50%, PEEP:0 cmH₂O, inspiratory pressure: 35 cmH₂O, respiratory rate: I/E:1/3.5) were made to prevent barotrauma and to decrease air trapping. Rocuronium infusion was started. Salbutamol/ipratropium and budesonide by nebulizer, iv magnesium and methylprednisolone were repeated to provide bronchodilation. The patient was hypotensive; in addition to adequate fluid repletion, noradrenaline iv infusion was started and titrated to achieve the mean arterial pressure >65 mmHg. A repeat ABG 30 minutes later showed a little improvement with a pH: of 7.25, PaO₂:87 mmHg, PaCO₂:69 mmHg, SaO₂: %96, HCO₃:25 mmol/L. However, the ABG 8 hours after ICU admission showed worsening of the hypercapnia (PaCO₂:87 mmHg) and acidosis (pH: 7.15) then we decided to initiate ECCO₂R. The left femoral vein was cannulated using a 12 F, 20 cm double-lumen catheter. The multiECCO₂R CO₂ removal filter (Eurosets, Italy) is connected in series with a continuous renal replacement device (Fresenius Medical Care, Germany). The system was set up at a 200 ml/min flow rate and sweep gas flow

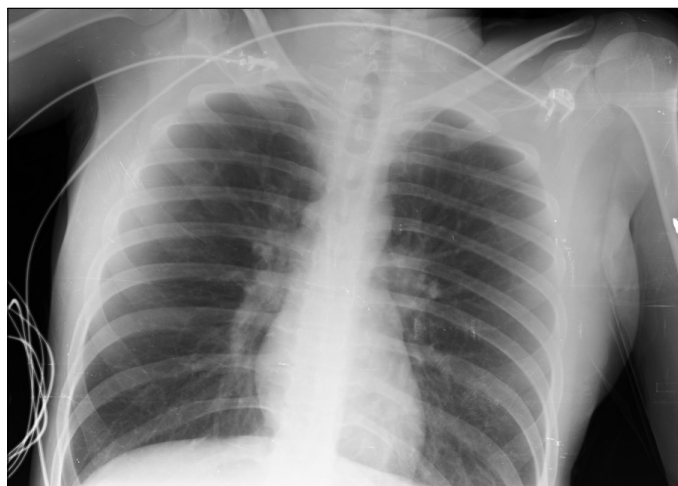

Figure 1. Chest X-Ray

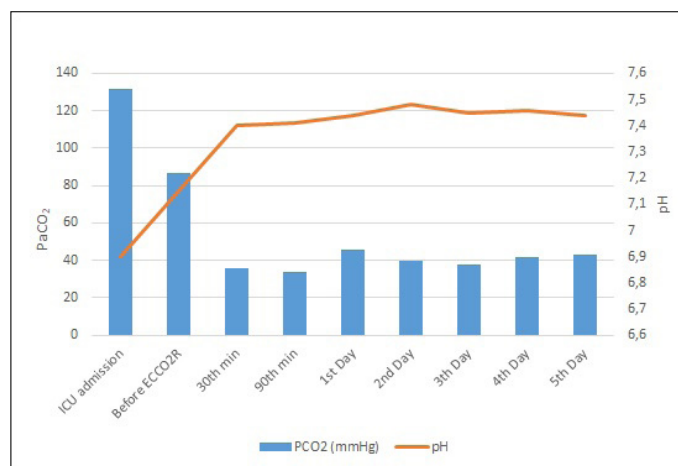


Figure 2. Temporal changes in pH and PaCO₂

of 4 L/min. The patient was started on ECCO₂R at the bedside. An ABG obtained 30 minutes later revealed an improved pH and PaCO₂.

During the follow-up, sweep gas flow and mechanical ventilation parameters were adjusted according to blood gas analysis (Figure 2, Table 1).

Sedation and neuromuscular blocker therapy were discontinued on the fourth day of ICU stay as the patient's bronchospasm receded, and adequate tidal volume could be achieved on mechanical ventilation. Sweep gas flow had been gradually reduced, and the patient was weaned from ECCO₂R successfully on day 5. Afterwards, the patient was extubated and received oxygen therapy via nasal cannula. She was transferred to the ward on day 8.

Discussion

Mechanical ventilation of a near-fatal asthma patient could be challenging for clinicians. Peak inspiratory pressure and intrinsic positive end-expiratory pressure increase due to excessive airway resistance and dynamic hyperinflation. In these patients, volume-

Table 1. Mechanical ventilator and ECCO₂R settings with arterial blood gas analysis

	Mechanical Ventilator Mode	FiO ₂ (%)	PEEP (cmH ₂ O)	Inspiratory Pressure (cmH ₂ O)	Respiratory Rate	pH	PaCO ₂ (mmHg)	Sweep Gas Flow (L/min)
ICU admission								
30 th minute	PC/AC	70	0	35	16	6.99	132	-
60 th minute	PC/AC	50	0	35	16	7.16	94	-
90 th minute	PC/AC	50	0	35	16	7.20	80	-
2 nd hour	PC/AC	40	0	35	16	7.23	72	-
3 rd hour	PC/AC	40	0	35	16	7.26	63	-
4 th hour	PC/AC	40	0	35	20	7.25	70	-
6 th hour	PC/AC	40	0	35	20	7.25	69	-
8 th hour	PC/AC	50	0	35	20	7.15	86	-
Under ECCO₂R								
30 th minute	PC/AC	40	3	35	20	7,40	36	4
90 th minute	PC/AC	40	3	32	20	7,41	34	3
1 st day	PC/AC	40	3	35	16	7,44	46	3
2 nd day	PC/AC	40	3	30	16	7,48	40	4
3 rd day	PC/AC	35	3	30	16	7,45	38	4
4 th day	PC/SIMV	35	4	18	16	7,46	42	3
5 th day	PSV	35	4	16	16	7,44	43	3

PC/AC: Assisted pressure control ventilation, PC/SIMV: Pressure control synchronized intermittent mandatory ventilation, PSV: Pressure support ventilation, FiO₂: Fraction of oxygen, PEEP: Positive end-expiratory pressure, PaCO₂: Partial arterial carbon dioxide pressure

controlled ventilation modes are recommended to avoid volume trauma due to airway resistance that can change suddenly. However, peak inspiratory pressure may need to rise to maintain adequate tidal volume (6 ml/kg). High inspiratory pressure increases the risks of barotrauma and pneumothorax. Hemodynamic instability may also develop with ventricular interdependence, increased right ventricular pressure, and decreased venous return (11). Reducing the tidal volume and inspiratory flow is recommended to prevent barotrauma (12). Pressure control ventilation was preferred in our case due to hemodynamic instability and a history of bilateral pneumothorax.

Intrinsic PEEP reduction should be aimed when adjusting mechanical ventilators in patients with asthma exacerbations because of the prolongation of the bronchospasm-related alveolar time constant and the slow emptying of the alveoli. (12) Interventions aimed at this goal can be listed as follows: reducing the respiratory rate, decreasing the I/E ratio (1/4 or 1/5), increasing the inspiratory flow (80-100 L/min), shortening the inspiratory time, and decreasing the minute ventilation. However, hypoxemia can be worsened with these arrangements (13). The administration of extrinsic PEEP can lead to increase air trapping in these patients. Positive end-expiratory pressure should be adjusted to 0 cmH₂O in paralyzed patients who do not have spontaneous breathing (14). In these patients, when airway resistance is relieved with medical treatment, ventilation-perfusion mismatch improves, and hypercapnic respiratory failure resolves quickly. However, respiratory failure can be life-threatening in cases with airway obstruction unresponsive to treatment, despite effective mechanical ventilation strategies.

Extracorporeal life support (ECLS) systems can be used as a rescue manoeuvre in these circumstances. Extracorporeal carbon dioxide removal is a form of ECLS aimed at removing CO₂. In patients whose oxygenation can be maintained with a mechanical ventilator, but persistent hypercapnia is present, ECCO₂R can be used as a rescue therapy. In the ECCO₂R system, venous blood drawn by the pump is passed through a semi-permeable filter that removes carbon dioxide and is returned to the patient through the venous route (15). It improves respiratory acidosis so ventilatory support can be decreased and ventilatory-associated lung injury can be prevented (16). Due to the differences in the dissociation and diffusion of oxygen and CO₂, lower flow rates (200 -1500 ml/min) are sufficient for ECCO₂R compared to conventional ECMO. Therefore, treatment can be successfully performed with 13-18 F double-lumen catheters and continuous renal replacement therapy devices (17).

There are many case reports about the successful usage of ECCO₂R in severe asthma attacks (18-20).

In a retrospective study conducted by Bromberger et al., it was found that ECCO₂R improves vital signs, peak inspiratory pressure, and intrinsic PEEP levels and decreases the need for vasopressor therapy in patients with severe asthma attacks. In the subgroup of patients weaned from the invasive mechanical ventilator during ECCO₂R support, the median duration of filter usage time was 3 [2-3] days. The median duration of invasive mechanical ventilation was 3 [1-5] days. In the subgroup of patients who were ventilated invasively during ECCO₂R support, the median duration of filter usage was 8 [3-9] days, while the

duration of invasive mechanical ventilation was 18 [6-36] days. While all patients in this study survived, the most common complication was deep vein thrombosis (46%) (10). We didn't extubate the patient during the ECCO₂R due to severe dynamic hyperinflation and low lung compliance. Although ECCO₂R blood flow rate and sweep gas flow were lower compared to the current case series, our patient had a rapid improvement in vital signs and respiratory acidosis, and the need for vasopressor therapy was eliminated in a short time. This can be explained by the improvement in myocardial depression triggered by acidosis and the decrease in right ventricular pressure due to low ventilation intensity during ECCO₂R. In our case, ECCO₂R

and invasive mechanical ventilation duration were relatively low compared to the literature. We did not observe any complications in the patient during intensive care and ward follow-up.

In conclusion, patients with near-fatal asthma should be managed carefully. Mechanical ventilation settings should be done optimally in these patients due to the presence of barotrauma risk and life-threatening respiratory acidosis. Extracorporeal life support systems could be beneficial in patients that are hard to manage with invasive mechanical ventilation. In cases where oxygenation can be maintained with a mechanical ventilator, and persistent hypercapnia is present, ECCO₂R is indicated.

AUTHOR CONTRIBUTIONS:

Concept: PH, CE; **Design:** PH, CE; **Supervision:** PH, CE; **Fundings:** PH, CE; **Materials:** PH, CE; **Data Collection and/or Processing:** PH, CE; **Analysis and/or Interpretation:** PH, CE; **Literature Search:** PH, CE; **Writing Manuscript:** PH, CE; **Critical Review:** PH, CE.

Informed Consent: Consent was taken from the patient

Peer-review: Externally peer-reviewed.

Conflict of Interest: Authors have no conflicts of interest to declare.

Financial Disclosure: The authors declared that this study has received no financial support.

Presentation: This case report was previously presented at the Turkish Respiratory Society 44th International Annual Congress as a poster presentation.

References

- Reddel HK, Taylor DR, Bateman ED, et al.; American Thoracic Society/European Respiratory Society Task Force on Asthma Control and Exacerbations. An official American Thoracic Society/European Respiratory Society statement: asthma control and exacerbations: standardizing endpoints for clinical asthma trials and clinical practice. *Am J Respir Crit Care Med.* 2009;180:59–99. [CrossRef]
- Ramnath VR, Clark S, Camargo CA Jr. Multicenter study of clinical features of sudden-onset versus slower-onset asthma exacerbations requiring hospitalization. *Respir Care.* 2007;52:1013–20. <https://rc.rcjournal.com/content/52/8/1013.short>
- Zheng X-Y, Orellano P, Lin H-L, et al. Short-term exposure to ozone, nitrogen dioxide, and sulphur dioxide and emergency department visits and hospital admissions due to asthma: A systematic review and meta-analysis. *Environ Int.* 2021;150:106435. [CrossRef]
- Yıldız F, Oğuzülgen IK, Dursun B, et al; TTS Asthma and Allergy Working Group Guideline Committee for Asthma. Turkish Thoracic Society asthma management and prevention guideline: key points. *Tuberk Toraks.* 2011;59:291–311. [CrossRef]
- D'Amato G, Vitale C, Lanza M, et al. Near fatal asthma: treatment and prevention. *Eur Ann Allergy Clin Immunol.* 2016;48:116–22. <http://www.eurannallergyimm.com/cont/journals-articles/427/volume-near-fatal-asthma-treatment-prevention-1137allasp1.pdf>
- McFadden ER Jr. Acute severe asthma. *Am J Respir Crit Care Med.* 2003;168:740–59. [CrossRef]
- Lee KH, Tan WC, Lim TK. Severe asthma. *Singapore Med J.* 1997;38:238–40, 243. <https://pubmed.ncbi.nlm.nih.gov/9294335/>
- Scoggin CH, Sahn SA, Petty TL. Status asthmaticus. A nine-year experience. *JAMA.* 1977;238:1158–62. [CrossRef]
- Louie S, Morrissey BM, Kenyon NJ, et al. The critically ill asthmatic—from ICU to discharge. *Clin Rev Allergy Immunol.* 2012;43:30–44. [CrossRef]
- Bromberger BJ, Agerstrand C, Abrams D, et al. Extracorporeal carbon dioxide removal in the treatment of status asthmaticus. *Crit Care Med.* 2020;48:e1226–31. [CrossRef]
- Laher AE, Buchanan SK. Mechanically ventilating the severe asthmatic. *J Intensive Care Med.* 2018;33:491–501. [CrossRef]
- Georgopoulos D, Kondili E, Prinianakis G. How to set the ventilator in asthma. *Monaldi Arch Chest Dis.* 2000;55:74–83. <https://pubmed.ncbi.nlm.nih.gov/10786431/>
- Leatherman JW, McArthur C, Shapiro RS. Effect of prolongation of expiratory time on dynamic hyperinflation in mechanically ventilated patients with severe asthma. *Crit Care Med.* 2004;32:1542–5. [CrossRef]
- Oddo M, Feihl F, Schaller M-D, et al. Management of mechanical ventilation in acute severe asthma: practical aspects. *Intensive Care Med.* 2006;32:501–10. [CrossRef]
- Conrad SA, Broman LM, Taccone FS, et al. The extracorporeal life support organization maastricht treaty for nomenclature in extracorporeal life support. A position paper of the extracorporeal life support organization. *Am J Respir Crit Care Med.* 2018;198:447–51. [CrossRef]
- Gattinoni L, Agostoni A, Pesenti A, et al. Treatment of acute respiratory failure with low-frequency positive-pressure ventilation and extracorporeal removal of CO₂. *Lancet.* 1980;2:292–4. [CrossRef]
- Combes A, Brodie D, Aissaoui N, et al. Extracorporeal carbon dioxide removal for acute respiratory failure: a review of potential indications, clinical practice and open research questions. *Intensive Care Med.* 2022;48:1308–21. [CrossRef]
- Mohammadian M, Mowafy A, Dikhtyar A. Successful utilization of life-saving extra-corporeal CO₂ removal in catastrophic status asthmaticus: a case report. *J Community Hosp Intern Med Perspect.* 2022;12:61–5. [CrossRef]
- Tiruvoipati R, Haji K, Gupta S, Braun G, Carney I, Botha J. Low-flow veno-venous extracorporeal carbon dioxide removal in the management of severe status asthmatics: a case report. *Clin Respir J.* 2016;10:653–6. [CrossRef]
- Di Lascio G, Prifti E, Messai E, et al. Extracorporeal membrane oxygenation support for life-threatening acute severe status asthmaticus. *Perfusion.* 2017;32:157–63. [CrossRef]